



PRESENTING CLINICAL SIGNS

DATE History: Low-grade left-sided murmur. Pre-anesthetic evaluation (dental).

1/24/23 ECHOCARDIOGRAPHIC FINDINGS

2D, M-mode, and Doppler study.

PERFORMED BY: Left atrial size is normal. The mitral valve leaflets are very mildly thickened, and a very mild jet of mitral regurgitation is present. Left ventricular dimensions are normal. Left ventricular systolic function is hyperdynamic. The aorta and aortic valve are normal. Right atrial and right ventricular dimensions are normal. The tricuspid is normal. The pulmonary artery and pulmonic valve are normal. No heartworms are visualized. No shunting lesions are visualized. No pericardial effusion or cardiac masses are seen.

Dr. Meredith Swart

INTERPRETED BY

Keith Blass, DVM,
MS, DACVIM
(Cardiology)

LA - 26.5 mm
LVIDd - 23.1 mm
LVIDs - 11.0 mm
FS - 52.3%

PATIENT

Rico Edwards

RA - 17.5 mm
LVOT - 1.42 m/s
RVOT - 0.92 m/s

ASSESSMENT/RECOMMENDATIONS

SPECIES

Canine

Degenerative mitral valve disease

BREED

Poodle Mix

This examination demonstrates very mild regurgitation of blood across Rico's mitral valve resulting from degenerative valve disease. The hemodynamic effects of the regurgitation also appear to be mild, as Rico does not have secondary dilation of either of her left heart chambers, and his left ventricular systolic function is well-preserved. As such, Rico's mitral valve disease appears to be well-compensated, and his current risk for the development of clinical signs secondary to it, such as coughing, exercise intolerance, syncope, and labored breathing, appears to be low.

SEX

MI

Rico's cardiovascular risk for general anesthesia is low based on this exam, though I still recommend avoiding the use of alpha-2 agonists in the anesthetic protocol and reducing the IV fluid rate by 10% as a precaution.

No therapy is recommended at this stage of disease.

AGE

14 y

A recheck echocardiogram is recommended in 6-9 months to monitor for disease progression.

WEIGHT

14.9 lb

HOSPITAL NAME

Swart Veterinary
Imaging

REFERRING VET

Dr. Swart



DATE

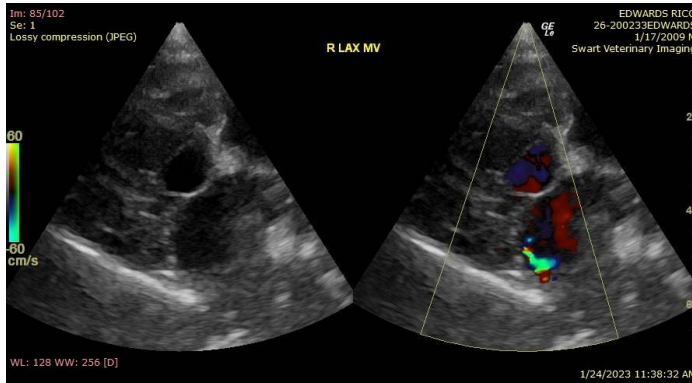
1/24/23

PERFORMED BY:

Dr. Meredith Swart

INTERPRETED BY

Keith Blass, DVM,
MS, DACVIM
(Cardiology)



The information and recommendations provided are based on the images presented by the referring veterinarian. No evaluation can be communicated regarding pathology that was not visible in the image/video clips provided.

Thank you for this referral. If the clinical or image interpretation does not parallel your findings or if I can be of any further assistance please contact me.

PATIENT

Rico Edwards

Keith Blass, DVM, MS, DACVIM (Cardiology)
KeithBlass@gmail.com
631-804-5754

SPECIES

Canine

BREED

Poodle Mix

SEX

MI

AGE

14 y

WEIGHT

14.9 lb

HOSPITAL NAME

Swart Veterinary
Imaging

REFERRING VET

Dr. Swart